

Volume 24 • No.2

Summer/Fall 2007

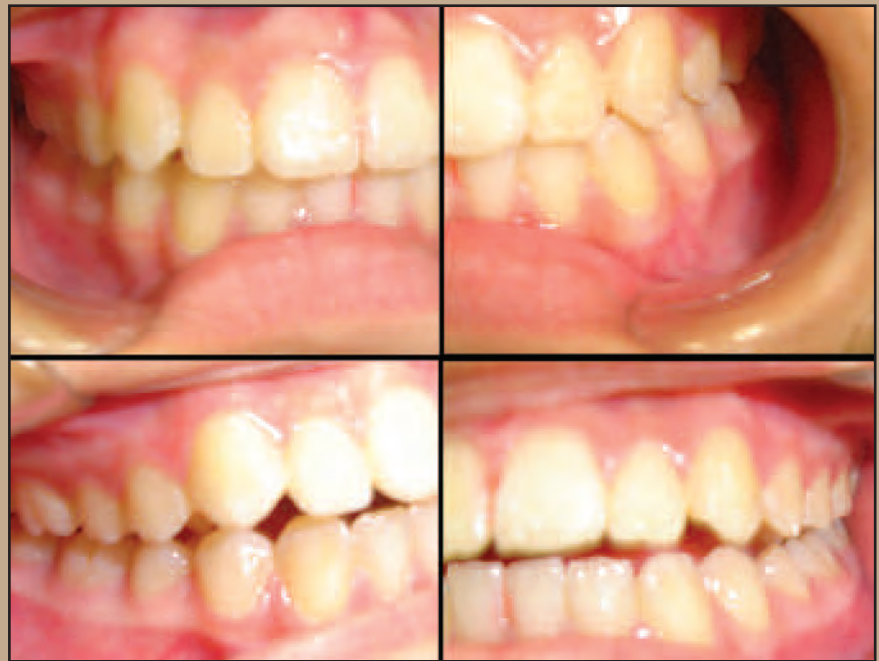

# The Functional Orthodontist

A Journal of Functional Jaw Orthopedics

**Report on  
Cranio-mandibular and  
Temporomandibular  
Joint Disorders**  
*by Dr. Terrance J. Spahl*

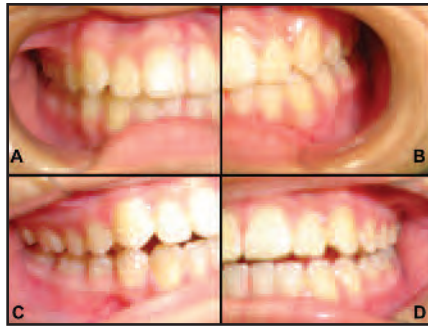**What Would You Do?**  
*by Dr. Philip J. Pistolas*



**A Case Study:**

## **Combining Functional and Fixed Appliances to Improve Results in Open Bite Treatment**

*by Dr. German O. Ramirez-Yanez*



# A CASE REPORT: Combining Functional and Fixed Appliances to Improve Results in Open Bite Treatment

by Dr. German O. Ramirez-Yanez and Dr. Guarim dos Anjos Jacira



**Dr. German O. Ramirez-Yañez**  
Assistant Professor  
Marquette University  
School of Dentistry  
Department of Developmental  
Sciences  
1801 W. Wisconsin Ave, Rm 322  
Milwaukee, WI 53233  
german.ramirez@marquette.edu



**Dr. Guarim dos Anjos Jacira,**  
Specialist in Orthodontics and  
Maxillo-Facial Orthopedics,  
Private Practice, Sao Paulo, Brazil

## ABSTRACT

Open bite is one of the most challenging malocclusions and its treatment must aim to improve occlusion and muscular function in the masticatory system, producing a satisfactory and stable result. This clinical report presents a patient with an open bite in mixed dentition associated with a Class II, division 1 malocclusion and a posterior unilateral crossbite. By combining functional and fixed appliances, the open bite was closed, a good occlusion was reinstated and muscular activity was improved in a simpler way. Therefore, this case report supports the idea of including myofunctional treatment when an open bite is treated at an early age.

Open bite is considered one of the most challenging malocclusion and its treatment must lead to improve occlusion and oral function producing a satisfactory and stable result.<sup>1-3</sup> As open bite treatment in adults may frequently require surgical procedures,<sup>4-6</sup> and the malocclusion may lead to TMD development<sup>7-10</sup>, the earlier this malocclusion is corrected, the better the prognosis will be.<sup>11-13</sup>

Non-nutritive sucking habits, muscular dysfunctions of the facial, masticatory and tongue muscles as well as allergic rhinitis have been referred as main causative factors for this malocclusion.

<sup>2,11,14-17</sup> As a result, various structures in the craniofacial complex are altered in open bite patients,<sup>1,18-21</sup> causing an increment in the gonial angle value<sup>1,21</sup> and a posterior rotation of the mandible.<sup>20</sup>

Generally, a palatal crib is used to

treat open bites in primary and mixed dentitions. However, this fixed appliance appears to have a dentoalveolar effect rather than modifying maxillary and mandibular skeletal discrepancies.<sup>22</sup> Another proposed treatment is rapid molar intrusion.<sup>23</sup> This type of treatment does not require patient compliance, but there are some reports regarding to the association between treating open bites with that technique and the appearance of functional problems and TMD during or after orthodontic treatment.<sup>24,25</sup>

Treatment stability is better achieved when the causative factors are identified and eliminated, and normal growth pattern is restored.<sup>2,26,27</sup> Conventional orthodontic treatment is generally based on a static evaluation.<sup>27</sup> Nevertheless, diagnosis and therapy should go further and consider muscular activity of the craniofacial muscles and tem-

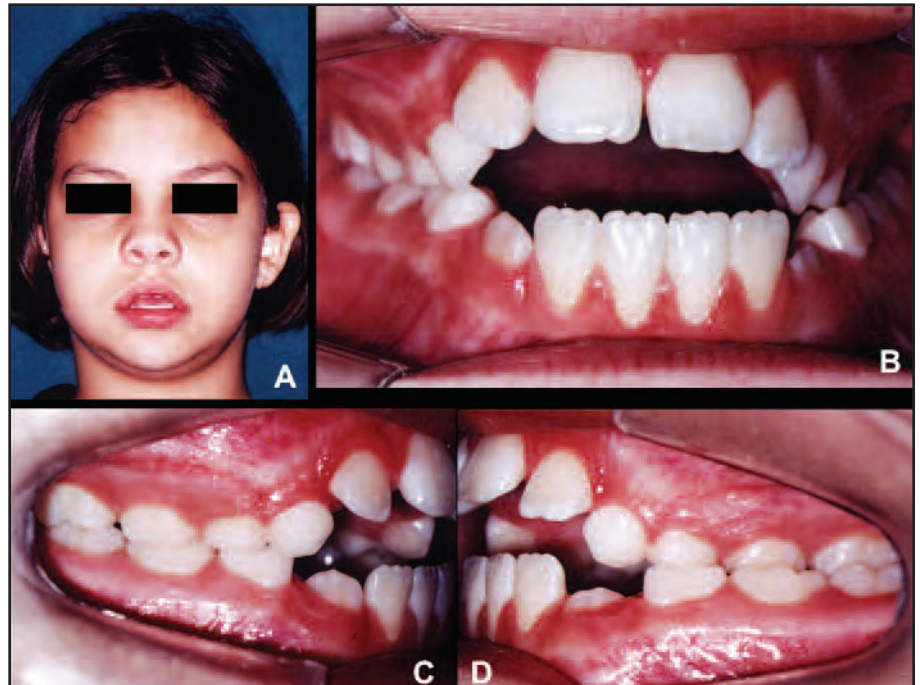poromandibular joint function.<sup>27-30</sup> The Trainer for Kids (T4K, Myofunctional Research Co., Australia), a pre-fabricated functional appliance, has demonstrated to improve function in facial, tongue and masticatory muscles, which altered muscular activity may worsen malocclusions.<sup>31,32</sup> Also, this pre-fabricated functional appliance has demonstrated to improve the inter-maxillary relationship in Class II, division 1 malocclusions,<sup>31-33</sup> stimulate transverse development and improve the vertical facial pattern.<sup>32</sup>

This paper describes a clinical case where an open bite in mixed dentition was treated with a combined approach, where the Trainer for Kids (T4K, Myofunctional Research Co, Australia) was used during the phase I, and then, tooth alignment was achieved with fixed orthodontics. By combining both myofunctional and fixed appliances, treatment became simpler and less aggressive, patient's compliance was improved and incisors' inclinations as well as intermaxillary relationship were better at the end of treatment.

### Case Report

A girl aged 8 years, 10 months, in mixed dentition presented with an open bite associated with a posterior crossbite on the left side from the primary first molars to the permanent first molars (Figure 1). The mandible was shifted to the left side in maximum intercuspation and the lower midline was deviated toward the left side as well. The patient did not maintain lip seal and she mainly breathed through her mouth (Figure 1A). Additionally, she sucked her thumb at home during daytime and when sleeping.

Cephalometric measurements performed before and after treatment on the lateral x-ray are shown in Table 1. Before treatment, the mandible was properly positioned (SNB angle), and there were no significant alterations in the values for



**Figure 1.** Photographs of the patient before treatment: (A) Frontal view of the patient with lips unsealed which is characteristic in mouth breathers; (B) Frontal view of the occlusion showing an open bite; (C) Lateral view of the occlusion on the right side; and, (D) lateral view of the occlusion on the left side showing a posterior crossbite.

the gonial (total, upper and lower), nasal plane and inferior facial height angles. Conversely, the maxilla was positioned forward (SNA angle) altering the inter-maxillary relationship (ANB angle), and incisors' inclination values were higher in both upper and lower dental arches. Measurements on the casts showed good transverse devel-

opment and no crowded teeth during the initial exam. However, the patient was unable to perform mandibular excursions mainly because the occlusal interference at the crossbite side. Therefore, the patient was diagnosed as Class II, division 1 malocclusion associated with forward position of the maxilla and incisors tipped buccally, and

Angle	Normal Value	Before Treatment	End of Treatment
SNA	82°	85.5°	82.5°
SNB	80°	80.5°	80°
ANB	2°	5°	2.5°
Gonion—Total Angle	130°	120°	120°
Gonion—Upper Angle	55°	49°	50°
Gonion—Lower Angle	75°	71°	70°
Nasal Plane/Pt Line	90°	89°	90°
Inferior Facial Height	47°	47°	46°
1/NA	23°	31°	28°
1/NB	25°	33°	25.5°

**Table 1.** Cephalometric measurements before and after treatment for the clinical case reported in this paper. Normal values were taken from Martins.<sup>41</sup> **SNA:** Sella-Nasion-Point A; **SNB:** Sella-Nasion-Point B; **ANB:** Point A-Nasion-Point B; **Gonion Total:** Articulare-Gonion-Menton; **Gonion Upper:** Articulare-Gonion-Nasion; **Gonion Lower:** Nasion-Gonion-Menton; **Nasal Plane/Pt Line:** Anterior Nasal Spine-Posterior Nasal Spine/Pterigoid point perpendicular to Frankfort; **Inferior Facial Height:** Anterior Nasal Spine-Xi-Suprapogonion; **1/NA:** Longitudinal axis of the upper incisor/Nasion-point A; **1/NB:** Longitudinal axis lower incisor/Nasion-point B.

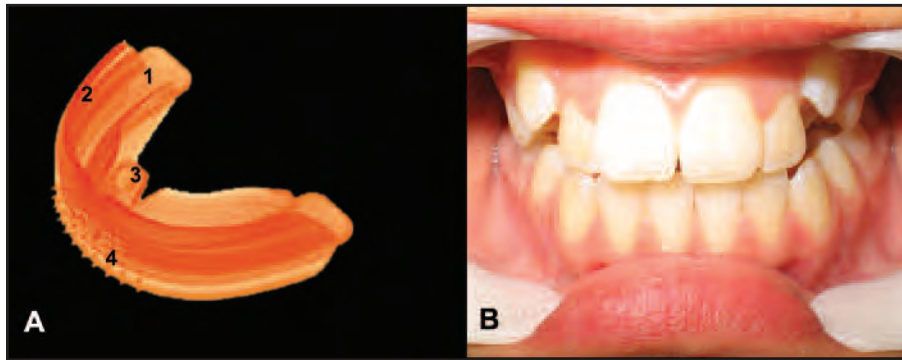


Figure 2. (A) The Trainer for Kids (T4K) used to treat the open bite in the clinical case presented in this report. The different features of the functional appliance are shown: (1) Channels to produce mandibular advance to an edge to edge position; (2) Buccal shields to separate the cheeks from the dental arches; (3) Lingual tab to exercise the tongue in an upward and retruded position; (4) Rugosities designed to decrease muscular activity in the mental region. (B) Open bite closed at the end of the phase I after 18 months of treatment with the T4K.

also, unilateral posterior crossbite.

The treatment goal was to close the bite and correct the crossbite before the eruption of the canines and premolars. A modified quad-helix was initially used to correct the crossbite and discourage thumb sucking<sup>34</sup>. However, there was no patient's compliance and she

removed the quad-helix and refused to use it after several months. Therefore, the plan of treatment was modified and the T4K (Figure 2A) was proposed as phase I treatment followed by fixed orthodontics after patient's compliance was improved. The patient wore the T4K as recommended by the manufacturer, 1-2

hours at day time and overnight.

After 1 month of treatment with the T4K, good patient's compliance was achieved and the patient quit sucking her thumb. Eighteen months later, the open bite was closed and the crossbite was corrected (Figure 2B). Although, the midline in the lower dental arch was slightly better, it continued deviated toward the left side. At this moment, fixed orthodontics (straight-wire technique) was used for tooth alignment. Brackets were removed 18 months later and the case was finished in a Class I occlusion with normal overbite and overjet (Figure 3). Cephalometrically, an improvement in the SNA angle and the incisors inclination values was observed at the end of treatment (Table 1 and Figure 4). SNB, gonial, nasal plane and inferior facial height angles did not vary when comparing their values before and after treatment (Table 1). At the end of active treatment, the midline on the lower dental arch remained deviated toward the left side. This matter was discussed with the patient and her parents and they refused to consider either disking or extending the treatment to improve this situation.

The patient has been followed up during three years post-treatment and bilateral mastication has been encouraged. She wore the Trainer for Alignment (T4A, Myofunctional Research Co, Australia) as retainer during the first 12 months post-treatment, and then, it was discontinued and no retention was provided afterwards. Up today, there are no signs of relapse either of the open bite, crossbite or tooth alignment (Figure 5A-B). Mandibular excursions are properly performed (Figure 5C-D), which suggest muscular function has continued to improve and craniofacial growth and development has been reestablished to normal physiological patterns. A slight improvement in the lower midline is observed after three years of treatment (Figure 5A).

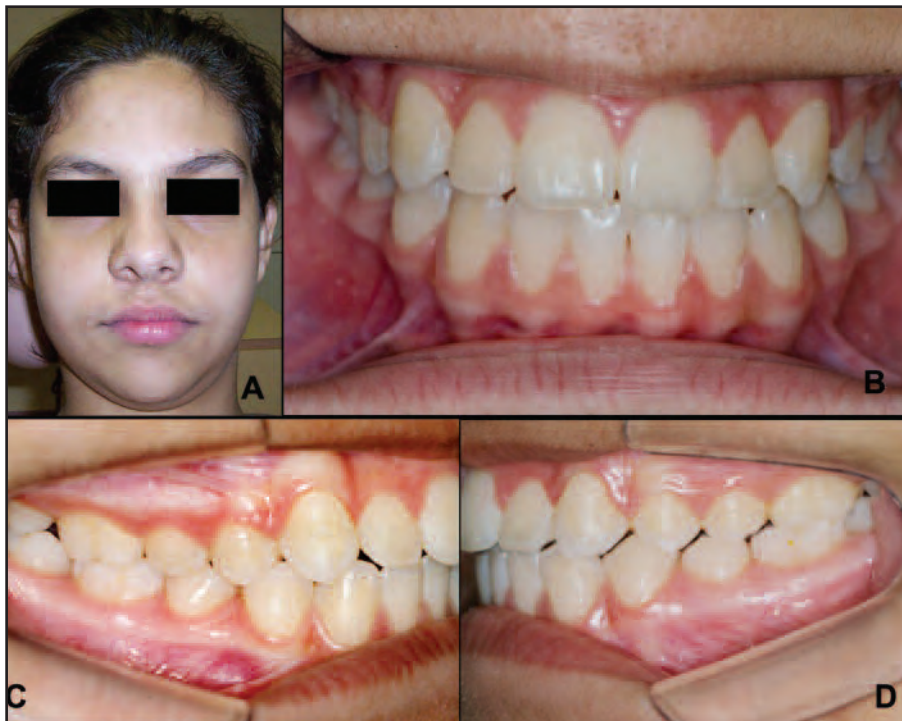

Figure 3. Photographs of the patient at the end of treatment with fixed orthodontics used for tooth alignment during phase II. (A) Frontal view of the patient maintaining lips seal and showing less muscular activity in the mental region comparing with figure 1A; (B) Frontal view of the occlusion at the end of treatment. A slight deviation of the midline in the lower dental arch remained at the end of treatment; (C) Lateral view of the occlusion on the right side with first molars and canines in Class I relationship at the end of treatment; (D) Lateral view of the occlusion on the left side with the crossbite corrected and Class I relationship at the first molars and canines.

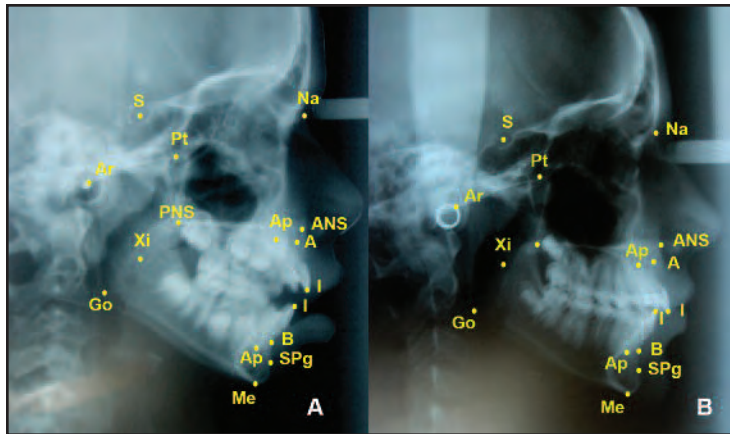


Figure 4. Lateral cephalograms before (A) and after (B) treatment showing the cephalometric points used to compare changes produced by the treatment. S = Sella; Na = Nasion; A = Point A; B = Point B; Pt = Point pterigoid; ANS = Anterior nasal spine; PNS = Posterior nasal spine; Ar = Articulare; Go = Gonion; Me = Menton; Xi = Center of the mandibular ramus; SPg = Supra-pogonion

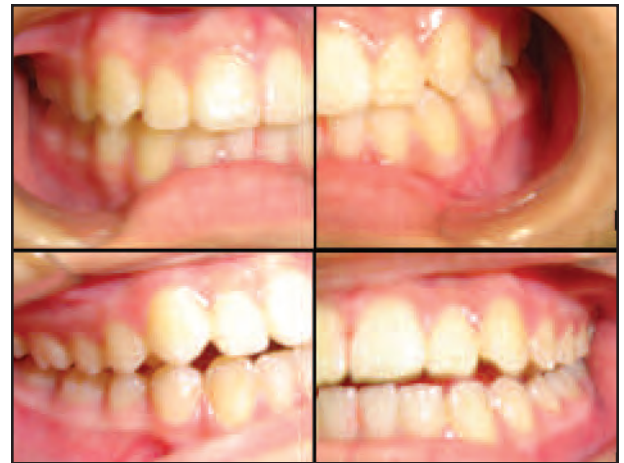

Figure 5. Occlusion of the patient on the right (A) and left (B) sides after three years of treatment. (C) (D) Mandibular excursions are smoothly performed toward both sides without interference. Patient wore a functional appliance as retainer for one year and no retention is maintained at this time.

## Discussion

This paper reports an open bite associated with Class II, division 1 malocclusion and unilateral posterior crossbite, which was treated by combining myofunctional and fixed techniques. This combined approach permitted firstly to close the open bite by discouraging thumb sucking and controlling tongue thrust. Using the T4K also corrected the posterior unilateral crossbite mainly caused by occlusal interference on the crossbite side. Then, fixed orthodontics was only required for tooth alignment and finishing this clinical case, simplifying the treatment and preventing to perform a more aggressive treatment that could be required if this patient would have been treated at adolescence or adulthood.

Open bite is recommended to be treated as soon as it is diagnosed.<sup>11-13</sup> This malocclusion results from an interaction between various etiological factors including bad oral habits, mouth breathing, muscular dysfunctions and skeletal abnormalities.<sup>5</sup> Thus, treating this type of malocclusion must goal to reinstate an ideal occlusion, improve oral and breathing functions and properly reestablish normal muscular activity in the masticatory, facial and tongue muscles. In this context, fixed appliances appear to produce

the required dentoalveolar modifications, which may close the open bite<sup>22,23</sup>. However, concerns regarding functional disturbances with these techniques during or after treatment have arisen<sup>24,25</sup>, and common techniques, such as palatal crib and molar intrusion, do not modify either the inter-maxillary sagittal relationship or the vertical facial pattern<sup>22</sup>.

In the clinical case reported here, a myofunctional approach allowed discouraging a non-nutritive sucking habit; control tongue thrust and closes the open bite. An improvement of muscular activity on the facial muscles was also clinically observed by the authors as it may be seen comparing figures 1A and 3A. Additionally, the unilateral posterior crossbite was corrected with the pre-fabricated functional appliance during treatment phase I. Thus, it appears that the T4K may be used to treat the Class II, division 1 malocclusion associated to either open bite and/or posterior unilateral crossbite. Also, this clinical report supports the idea of treating open bite malocclusions at an early age with functional appliances, which may result in improved oral function and produce more stable results<sup>35,36</sup>. Nevertheless, long-term clinical outcomes need to be further evaluated to compare treatment effective-

ness and relapse occurrences between functional and fixed techniques when treating open bites at an early age.

One of the biggest concerns regarding functional (removable) appliances is patient's compliance, which is the most common reason for dentist to more frequently treat with fixed rather than removable appliances. In this case, the patient refused to use a modified quad-helix, a fixed appliance initially designed to control thumb sucking and expand the maxilla to correct the crossbite. On the contrary, the T4K being used by the patient during a couple of hours at day time and overnight, was fully accepted with no complain and successfully corrected the crossbite, closed the open bite and discourage thumb sucking in the patient. Therefore, it seems that getting good patient's compliance with functional appliances may be more related with the ability of the professional to motivate and encourage the patient to use the appliance than the discomfort, pain or speech difficulties associated with those orthodontic techniques.<sup>37-39</sup>

The T4K has shown to change mandibular posture by moving the mandible forward in Class II, division 1 patients.<sup>31</sup> In the case presented in this clinical report, a class

II, division 1 malocclusion was diagnosed, but instead of presented with a backward position of the mandible (SNB angle value was normal), it was associated with a forward position of the maxilla (SNA angle value was increased). At the end of treatment, the SNA angle was closer to a normal value which suggests the T4K might have restricted anterior maxillary growth. Conversely, Usumez and co-workers reported a significant improvement in the inter-maxillary relationship of the subjects involved in their study by significantly increasing the SNB angle, but not by modifying the SNA angle. It must be remarked that in that study the subjects had a normal value for the SNA angle and reduced SNB angle before treatment. The patient reported in this paper presented the opposite situation regarding to those two angles. Thus, it looks like the T4K might also improve the inter-maxillary relationship in Class II, division 1 malocclusions by moving the mandible forward<sup>31</sup>, but also by restricting the maxillary growth and development when the maxilla is positioned forward, as it occurs with other orthodontic appliances.<sup>40</sup> By this means, the mandible may catch up with maxillary growth improving inter-maxillary relationship. Therefore, clinical studies involving Class II, division 1 malocclusion patients, where the malocclusion is associated with maxillary protrusion instead of mandibular retrusion, have to be done to further clarify the effect of this functional appliance on growth and development of the maxilla.

Another explanation of how craniofacial structures could be modified by the T4K during the course of treatment in this clinical case is because its effect on the incisors' dentoalveolar units. Usumez and co-workers<sup>31</sup> reported that the T4K modifies the inclination of both upper and lower incisors, which was also observed in a more recent clinical study.<sup>32</sup> In

this case, incisors' inclinations were improved in both dental arches bringing their values closer to normal. It may be hypothesized that during the course of treatment, the T4K caused a repositioning of the incisors changing their inclinations, which stimulated modeling of the whole dentoalveolar units. These changes in incisors inclination and modeling of their dentoalveolar units could produce modeling of the anterior aspect of the maxilla relocating the point A. However in the case reported here, the point B appears not being modified by treatment, even though there was a change in the inclination of the lower incisors. The two hypothetical effects proposed above for the T4K may have occurred in this patient, but as mentioned previously, more clinical studies involving treated cases with this functional appliance contrasted with control groups are required to fully understand the modus operandi of the T4K.

### Conclusions

This case report supports the idea of include myofunctional treatment when an open bite is treated at an early age. Combining functional and fixed appliances may help to improve oral functions and skeletal discrepancies when treating this type of malocclusion, and produces a more stable treatment.

### References

1. Beane RA, Reimann G, Phillips C, Tulloch C. A cephalometric comparison of black open-bite subjects and black normals. *Angle Orthod.* 73:294-300, 2003
2. Ramirez-Yanez GO, Farrell C. Soft tissue dysfunction: a missing clue when treating malocclusions. *Int J Jaw Funct Orthop.* 1:483-494, 2005
3. Kuroda S, Sugawara Y, Tamamura N, Takano-Yamamoto T. Anterior open bite with temporomandibular disorder treated with titanium screw anchorage:

- Evaluation of morphological and functional improvement. *Am J Orthod Dentofacial Orthop.* 131:550-560, 2007
4. Epker BN, Fish LC. Surgical orthodontic correction of open bite deformity. *Am J Orthod.* 71:278-299, 1977
5. Ngan P, Fields HW. Open bite: a review of etiology and management. *Pediatr Dent.* 19:91-98, 1997
6. Proffit WR, Bailey LJ, Phillips C, Turvey TA. Long-term stability of surgical open bite correction by Lefort I osteotomy. *Angle Orthod.* 70:112-117, 2000
7. Williamson EH. Temporomandibular dysfunction in pre-treatment adolescent patients. *Am J Orthod.* 72:429-433, 1977
8. Riolo ML, Brandt D, TenHave TR. Associations between occlusal characteristics and signs and symptoms of TMJ dysfunction in children and young adults. *Am J Orthod Dentofacial Orthop.* 92:467-477, 1987
9. Tanne K, Tanaka E, Sakuda M. Association between malocclusion and temporomandibular disorders in orthodontic patients before treatment. *J Orofac Pain.* 7:156-162, 1993
10. Pahkala RH, Laine-Alava MT. Do early signs of orofacial dysfunctions and occlusal variables predict development of TMD in adolescence? *J Oral Rehabil.* 29:737-743, 2002
11. Tausche E, Luck O, Harzer W. Prevalence of malocclusions in the early mixed dentition and orthodontic treatment need. *Eur J Orthod.* 26:237-244, 2004
12. Stuani MB, Stuani AS, Stuani AS. Modified Thurow appliance: a clinical alternative for correcting skeletal open bite. *Am J Orthod Dentofacial Orthop.* 128:118-125, 2005
13. Bishara SE, Warren JJ, Broffitt B, Levy SM. Changes in the prevalence of nonnutritive sucking patterns in the first 8 years of life. *Am J Orthod Dentofacial*

- Orthop. 130:31-36, 2006
14. Lowe AA, Johnston WD. Tongue and jaw muscle activity in response to mandibular rotations in a sample of normal and anterior open-bite subjects. *Am J Orthod.* 76:565-576, 1979
  15. Charchut SW, Allred EN, Needleman HL. The effects of infant feeding patterns on the occlusion of the primary dentition. *J Dent Child.* 70:197-203, 2003
  16. Cozza P, Baccetti T, Franchi L, Mucedero M, Polimeni A. Sucking habits and facial hyperdivergency as risk factors for anterior open bite in the mixed dentition. *Am J Orthod Dentofacial Orthop.* 128:517-519, 2005
  17. Vazquez-Nava F, Quezada-Castillo JA, Oviedo-Trevino S, Saldivar-Gonzalez AH, Sanchez-Nuncio HR, Beltran-Guzman FJ et al. Association between allergic rhinitis, bottle feeding, non-nutritive sucking habits, and malocclusion in the primary dentition. *Arch Dis Child.* 91:836-840, 2006
  18. Erbay E, Ugur T, Ulgen M. The effects of Frankel's function regulator (FR-4) therapy on the treatment of Angle Class I skeletal anterior open bite malocclusion. *Am J Orthod Dentofacial Orthop.* 108:9-21, 1995
  19. Tsang WM, Cheung LK, Samman N. Cephalometric characteristics of anterior open bite in a southern Chinese population. *Am J Orthod Dentofacial Orthop.* 113:165-172, 1998
  20. Meral O, Yuksel S. Skeletal and dental effects during observation and treatment with magnetic device. *Angle Orthod.* 73:716-722, 2003
  21. Claudio R, Claudio U, Alessandro A, Massimiliano T, Angelo M. Variations of the gonial angle in vertical surgical reduction of the maxillary-mandibular complex. *J Craniofac Surg.* 16:716-719, 2005
  22. Pedrin F, Almeida MR, Almeida RR, Almeida-Pedrin RR, Torres F. A prospective study of the treatment effects of a removable appliance with palatal crib combined with high-pull chin cup therapy in anterior open bite patients. *Am J Orthod Dentofacial Orthop.* 129:418-423, 2006
  23. Carano A, Machata W, Siciliani G. Noncompliant treatment of skeletal open bite. *Am J Orthod Dentofacial Orthop.* 128:781-786, 2005
  24. Henrikson T, Ekberg EC, Nilner M. Symptoms and signs of temporomandibular disorders in girls with normal occlusion and Class II malocclusion. *Acta Odontol Scand.* 55:229-235, 1997
  25. Egemark I, Blomqvist JE, Cromvik U, Isaksson S. Temporomandibular dysfunction in patients treated with orthodontics in combination with orthognathic surgery. *Eur J Orthod.* 22:537-544, 2000
  26. Martina R, Laino A, Michelotti A. Class I malocclusion with severe open bite skeletal pattern treatment. *Am J Orthod Dentofacial Orthop.* 97:363-373, 1990
  27. Bakke M, Moller E. Occlusion, malocclusion and craniomandibular function. In: Melsen B, editor. *Current controversies in orthodontics.* Chicago: Quintessence Publishing Co.; p. 77-101, 1991
  28. Graber T. The three M's: muscles, malformation and malocclusion. *Am J Orthod Dentofacial Orthop.* 49:418-450, 1963
  29. Graber TM. The use of muscle forces by simple orthodontic appliances. *Am J Orthod.* 76:1-20, 1979
  30. van der Linden FPGM, Proffit WR. *Orofacial functions.* Quintessence Publishing, 2004.
  31. Usumez S, Uysal T, Sari Z, Basçiftci FA, Karaman AI, Guray E. The effects of early preorthodontic Trainer treatment on Class II, division 1 patients. *Angle Orthod.* 74:605-609, 2004
  32. Ramirez-Yanez GO, Sidalaukas A, Junior E, Flutter J. The effect of a pre-fabricated functional appliance on transversal development. *J Clin Pediatr Dent.* 31:287-291, 2007
  33. Quadrelli C, Gheorgiu M, Marchetti C, Ghiglione V. Early myofunctional approach to skeletal Class II. *Mondo Orthod.* 2:109-122, 2002
  34. Henry RJ. Slow maxillary expansion: a review of Quad-helix therapy. *J Dent Child.* 60:1051-1058, 1993
  35. Haruki T, Kishi K, Zimmerman J. The importance of orofacial myofunctional therapy in pediatric dentistry: reports of two cases. *J Dent Child.* 66:103-109, 1999
  36. Dincer B, Hazar S. The functional treatment of anterior open bite: three case reports. *J Clin Pediatr Dent.* 25:275-286, 2001
  37. Serogl HG, Klages U, Zentner A. Pain and discomfort during orthodontic treatment: causative factors and effects on compliance. *Am J Orthod Dentofacial Orthop.* 114:684-691, 1998
  38. Serogl HG, Zentner A. A comparative assessment of acceptance of different types of functional appliances. *Eur J Orthod.* 20:517-524, 1998
  39. Doll GM, Zentner A, Klages U, Serogl HG. Relationship between patient discomfort, appliance acceptance and compliance in orthodontic therapy. *J Orofac Orthop.* 61:398-413, 2000
  40. Fotis V, Melsen B, Williams S. Posttreatment changes of skeletal morphology following treatment aimed at restriction of maxillary growth. *Am J Orthod.* 88:288-296, 1985
  41. Martins DC, G.R.P. J, de Almeida RR, Pinzan A, Henriques JF, de Freitas MR. *Atlas de crescimento craniofacial.* Sao Paulo: Livraria Santos; 1998.