

Dental Arches Expansion with Ortho-System

Maxillary and mandibular expansion has been proposed to increase the arch perimeter and to avoid extractions during orthodontic treatment. This paper describes a novel method to produce expansion of the dental arches, and at the same time, to treat muscular dysfunctions which may be the etiological factor of the malocclusion. Two cases treated with the Ortho-System are described and the advantage of this method of treatment is discussed.

Expansion of the jaws has been increasingly performed in orthodontics to achieve better occlusal and maxillary relationship, and so, to improve oral functions. Maxillary and mandibular expansion has been proposed since Edward Angle to avoid extractions (Dewel, 1964). This paper presents a novel method to produce dental arch development in the maxilla and the mandible, and at the same time, to correct or maintain the inter-maxillary relationship either if a sagittal and/or vertical problem exist or a Class I malocclusion with normal overjet and overbite is present at the beginning of treatment.

There is a controversy regarding the ideal time for performing the expansion. Sari and co-workers reported that rapid maxillary expansion by means of a fixed screw (eg. Hyrax) produces better results when it is performed in early permanent dentition (Sari, 2003). Although this statement appears to be supported by other studies (Chung; Housley, 2003; Spillane, 1995), maxillary expansion may also be successfully done in older adolescents and adults (Stuart, 2003; Iseri, 2004; Lima, 2000). In the maxilla, rapid and semi-rapid expansion produce an increase of the lower nasal and maxillary base widths, with the maxilla moving forward and downward (Chung, 2004; Sari, 2003; Iseri, 2004).

These changes in the maxilla produced by the expansion are accompanied by a spontaneous mandibular response, which increases the dental arch perimeter (Lima, 2004; McNamara, 2003) and rotates the mandible posteriorly (Sari, 2003; Chung, 2004). Mandibular displacement is associated with an increase in facial height (Sari, 2003, Chung, 2004).

Net gain in the arch perimeter may be calculated accordingly with the expansion performed. Motoyoshi and co-workers reported that 1 mm increase in arch width results in an increase in arch perimeter of 0.37 mm (Motoyoshi, 2002). Akkaya and collaborators determined that arch perimeter gain through expansion could be predicted as 0.65 times the amount of the posterior expansion when treatment is performed with rapid maxillary expansion, and 0.60 times the amount of posterior expansion when treatment is performed with semi-rapid maxillary expansion (Akkaya, 1998). This is also supported by Adkins and co-workers, who determined that arch perimeter may increase 0.7 times the expansion produced at the premolars.

An expected relapse in the amount of expansion has been reported by some authors (Hime, 1990; Housley, 2003), which appears to be the result of that pressure delivered by the cheeks on the maxillary arch and the resistance to deformation of maxillary sutures and surrounding tissues to maxillary expansion.

Nevertheless, maxillary and mandibular expansion rise up as one of the important phases of orthodontic treatment, producing arch perimeter increase, and so, avoiding teeth extractions. Thus, the aim of the current paper is to present a new method to produce maxillary and mandibular expansion, and at the same time, to treat soft tissue dysfunction that may be responsible for treatment relapse (Ramirez-Yañez, 2005). A couple of cases treated with the Ortho-System developed by Myofunctional Research Co in Australia are presented to explain the proposed treatment.

The Ortho-System

The Ortho-System is composed by two different appliances, the Trainer™ and the Farrell Bent Wire System (BWS). These two appliances combined may simultaneously produce arch development and treat the myofunctional habits. The Trainer™, a pre-fabricated functional appliance, has amply demonstrated to relocate the mandible (Usumez, 2004), to correct improper forces produced by the muscles of the cheek and lips (Quatrelli, Ramirez-Yañez, 2005a) and to change the dimensions of the dental arches (Ramirez-Yañez, 2005b). However, in those cases where more maxillary and mandibular expansion is required to avoid teeth extractions, the Trainer™ combined with the BWS produces higher amounts of expansion, and therefore, a higher increase in arch perimeter. The BWS is composed by a lingual arch which follows the lingual surfaces of the teeth's crown at the gingival third and ends in a loop at the inter-proximal space between the second premolar and the first molar at both sides. The distal end engages a tube (0.7 - Farrell tube, Leone, Italy) welded to a cemented band on the first molars (figure 1). Additionally, the BWS is maintained in place, facing the gingival third of teeth's crown, by two Begg premolar brackets cemented on the first premolars with the slot directed towards gingival (figure 2).

An advantage of this system is that it does not involve acrylic in the palate. A functional appliance designed with acrylic on the palate and which is not properly built, may lower the tongue encouraging tongue thrusting, and thus, either worsening the malocclusion or producing a relapse. The Trainer™ is a pre-fabricated functional appliance, which means no laboratory involvement, and the BWS can be entirely constructed "in office". The BWS neither is composed by acrylic nor occupy the palate, and so, permits a normal talking to the patient. The following two cases show the effect of the Ortho-System on arch development.

Case One

Female patient, 12 years old, who consulted because a crowded dentition involving ectopic eruption of both upper and lower canines on the right side (figure 3). Occlusion was classified as Class I with normal overjet and tendency to deep-bite. None skeletal alteration was found on cephalometric measurements and analysis of cast models reported a lack of arch development. This case was diagnosed as a Class I malocclusion with under-development of both dental arches. Thus, plan of treatment involved a first phase with a BWS on the upper arch combined with a Trainer™ for braces (T4B) over the first 6 months, and a second phase with a BWS on the lower arch combined with fixed orthodontics (Straight-Wire Appliance). After 6 months of treatment with BWS plus T4B, a great development of the upper arch was achieved (Figure 4), providing enough arch perimeter to align the upper teeth. An improvement in the inter-maxillary relationship was observed at that time, as deep-bite was corrected and the Class I was maintained (Figure 5). The second phase of treatment with the BWS on the lower arch produced a

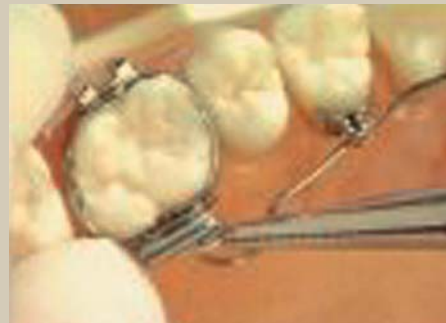

Figure 1 Picture showing the distal end of the lingual arch of the Farrell Bent Wire System engaging in the tube welded to a first molar band

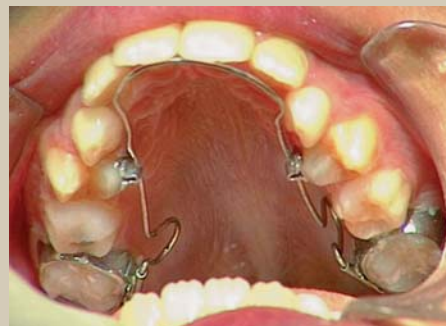

Figure 2 Picture showing the Farrell Bent Wire System placed in the upper arch

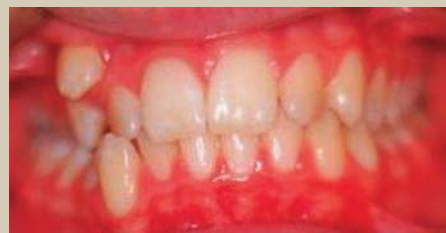

Figure 3 12 years old patient with a malocclusion Class I and ectopic eruption of the canines on the right side

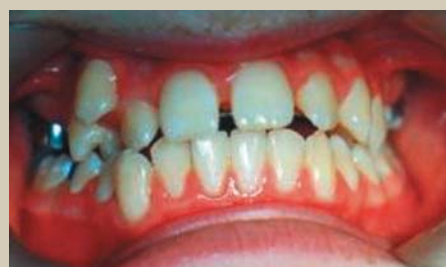

Figure 4 Diastemas are observed between the central incisors due to the arch development performed by the treatment. Note that the inclination of the incisors has not changed as the overjet has been maintained over the treatment

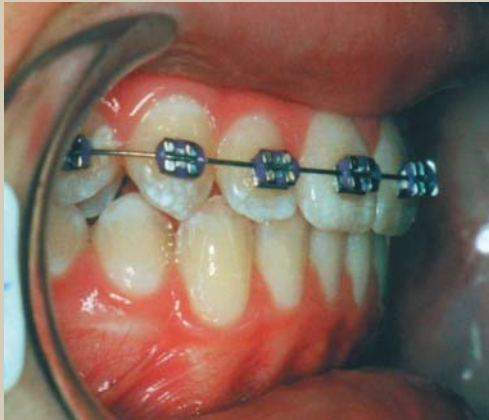


Figure 5 Upper teeth were aligned with brackets and the inter-maxillary relationship and the overjet were maintained over the treatment. Note that overbite has improved

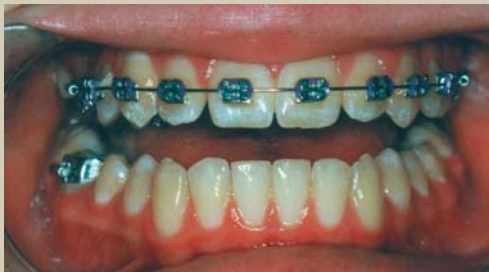
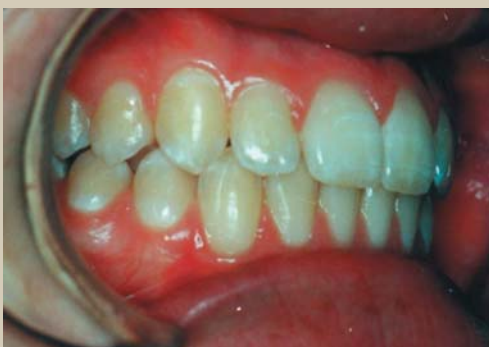
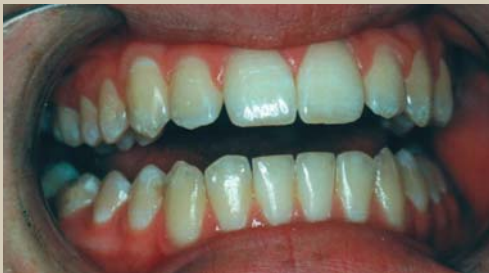Figure 6 Lower teeth were aligned by the action of the Ortho-System without using brackets



Figures 7 and 8 Pictures showing the case after 8 months of treatment

great arch development which permitted to align lower teeth without using fixed appliances (Figure 6). Thus, this case was treated in less than a year (Figures 7 and 8), achieving the goals of treatment, and most importantly, without extracting teeth due to arch development produced by the Ortho-System.

Case Two

Female patient, 10 years old, who consulted because the lateral incisor on the right side erupted on the palate (Figure 9). Occlusion was classified as Class I with normal overjet and overbite. No skeletal alterations of the craneo-mandibular structures were observed on the lateral x-ray. The analysis of the dental arches showed a lack of development, particularly on the upper arch. Thus, the plan of treatment involved a BWS on the upper arch combined with a Trainer™ for kids (T4K). The T4K was used by the patient 2 hours during daytime and at night when sleeping, particularly to correct the higher forces delivered by the muscles of the cheek (buccinator) and lips (orbicularis oris) at swallowing (Figure 10). After 4 months of treatment, the BWS produced enough upper arch development and moved the misaligned lateral incisor to a better position (Figure 11). Treatment continued with the BWS in place, but no active, and the T4K for 12 months more, when the goals of treatment were achieved (Figure 12). At the end of the treatment, no changes were observed on the inter-maxillary relationship maintaining the overjet and overbite present at the beginning of treatment. Furthermore, higher forces delivered by the peri-oral muscles at the beginning of treatment were significantly reduced.

Conclusions

Maxillary and mandibular expansion has been showed to be an excellent alternative to increase the arch perimeter, and thus, to avoid extractions to properly align teeth. This paper has presented two cases treated with the Ortho-System, which involves two appliances: the Trainer™, a pre-fabricated functional appliance, and the BWS. Both appliances, Trainer™ and BWS, have to be used in order to get the results reported in this paper. The Ortho-System showed in these two cases and in many cases treated by the authors that it is an excellent choice to produce arch development in both upper and lower dental arches in a short time. The effect of the Ortho-System on arch development does not change the inter-maxillary relationship when a Class I occlusion exists at the beginning of treatment. However, when a Class II malocclusion is present associated to crowded dentition, the Ortho-System produces arch development, and at the same time, the effect of mandibular relocation produced by the Trainer™ (Usumez, 2004; Ramirez-Yañez, 2005a; Quadrelli, 2002) treats the distal position of the mandible. Additionally, the Ortho-System has shown to improve the overjet and overbite, but to maintain them when they are correct at the beginning of treatment. This system treats muscular dysfunctions that may be the cause of

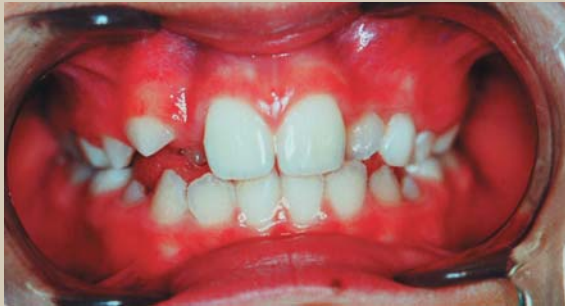

Figure 9 (above) 10 years old patient with a malocclusion Class I and ectopic eruption of the lateral incisors

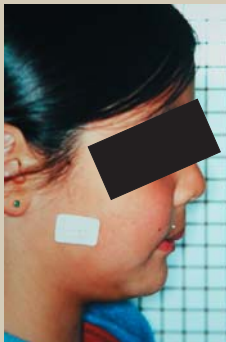

Figure 10 (left) Increased forces produced by the muscles of the cheeks and lips affect the normal developed of the dental arches and is clinically noted by the presence of a groove at the corners of the mouth

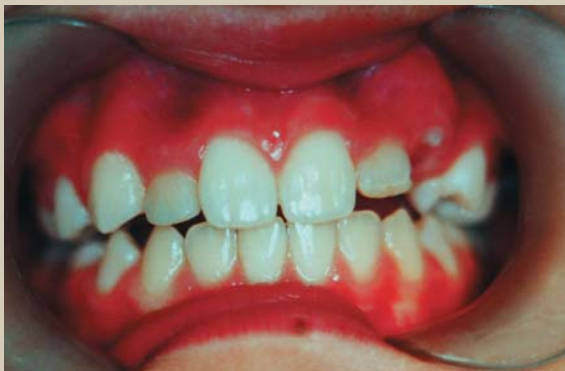
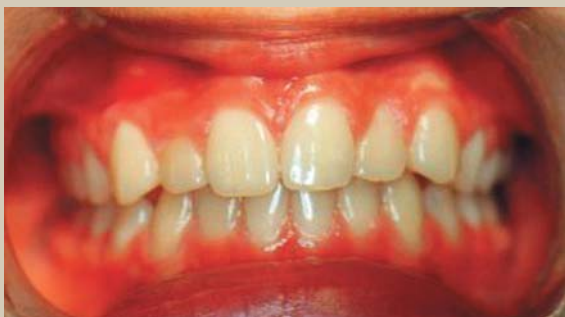
Figure 11 Arch development was achieved in the upper arch after 4 months of treatment with the Ortho-System



Figures 12 Pictures showing the case at the end of treatment

crowding and malocclusion and may cause relapse after treatment is finished. Thus, the Ortho-System may be proposed as an excellent alternative of treatment in those cases where arch development is required to align teeth, extractions wants to be avoided, patients want to minimize or even avoid brackets, mandible needs to be relocated, soft tissue dysfunction is present and treatment needs to be performed in reasonable time. **DA**

References

1. Adkins MD, Nanda RS, Currier GF. Arch Perimeter changes on rapid palatal expansion. Am J Orthod Dentofacial Orthop 1990; 97: 194-9
2. Akkaya S, Lorenzon S, Ucem TT. Comparison of dental arch perimeter changes between bonded rapid and slow maxillary expansion procedures. Eur J Orthod 1998; 20: 255-61
3. Chung CH, Font B. Skeletal and dental changes in the sagittal, vertical and transverse dimensions after rapid palatal expansion. Am J Orthod Dentofacial Orthop 2004; 126:569-75
4. Dewel BF. Serial extraction: its limitations and contraindications in orthodontic treatment. Am J Orthod 1967; 53: 904-21
5. Hime DL, Owen AH 3rd. The stability of the arch expansion effects on Frankel appliance therapy. Am J Orthod Dentofacial Orthop 1990; 98: 437-45
6. Housley JA, Nanda RS, Currier GF, McCune DE. Stability of transverse expansion in the mandibular arch. Am J Orthod Dentofacial Orthop 2003; 124: 288-93
7. Iseri H, Ozzoy S. Semirapid maxillary expansion – a study of long term transverse effects in older adolescents and adults. Angle Orthod 2004; 74: 71-8
8. Lima RM, Lima AL. Case report: Long-term outcome of Class II, division 1 malocclusion treated with rapid palatal expansion and cervical traction. Angle Orthod 2000; 70: 89-94
9. Lima AC, Lima AL, Filho RM, Oyen OJ. Spontaneous mandibular arch response after rapid palatal expansion: a long term study on Class I malocclusion. Am J Orthod Dentofacial Orthop 2004; 126: 576-82
10. McNamara JA Jr, Baccetti T, Franchi L, Herberger TA. Rapid maxillary expansion followed by fixed appliances: a long-term evaluation of changes in arch dimensions. Angle Orthod 2003; 73: 344-53
11. Motoyoshi M, Hirabayashi M, Shimazaki T, Nawra S. An experimental study on mandibular expansion: increases in arch width and perimeter. Eur J Orthod 2002; 24: 125-30
12. Quadrelli C, Gheorgiu M, Marchetti C, Ghiglione V. Early Myofunctional approach to skeletal Class II. Mondo Orthod 2002; 2: 109-22
13. Ramirez-Yañez GO, Farrell C. Soft tissue dysfunction: A missing clue when treating malocclusions. Int J Jaw Func Orthop 2005; 5 (in press)
14. Ramirez-Yañez GO, Junior E, Sidlauskas A, Flutter J, Farrell C. The effect of a pre-fabricated functional appliance on arch development. 2005 (in preparation)
15. Sari Z, Uysal T, Usumez S, Basçiftci FA. Rapid maxillary expansion. Is it better in the mixed or in the permanent dentition? Angle Orthod 2003; 73: 654-61
16. Spillane LM, McNamara JA Jr. Maxillary adaptation to expansion in the mixed dentition. Semin Orthod 1995; 1: 176-87
17. Stuart DA, Wilkshire WA. Rapid palatal expansion in the young adult: time for a paradigm shift? J Can Dent Assoc 2003; 69: 374-7
18. Usumez S, Uysal T, Sari Z, Basçiftci FA, Karaman AI, Guray E. The effects of early preorthodontic Trainer treatment on Class II, division 1 patients. Angle Orthod 2004; 74: 605-9



Dr German Ramirez-Yañez has more than 20 years of experience in guiding craniofacial growth and development. He is a specialist in Pediatric Dentistry and Functional Maxillofacial Orthopedics, as well as trained in Orthodontics. He is currently the scientific advisor of Myofunctional Research Co. in Australia and of Osteopharm Inc. in Canada.



Dr Chris Farrell is a specialist in Temporomandibular Joint Disorders (TMD) and orthodontics and orthotropics in Australia. He developed the TRAINER system and other appliances, pioneering the use of CAD for intraoral appliances and holds four world patents for prefabricated appliances for myofunctional TRAINING, TMD treatment and new mouthguard technology.